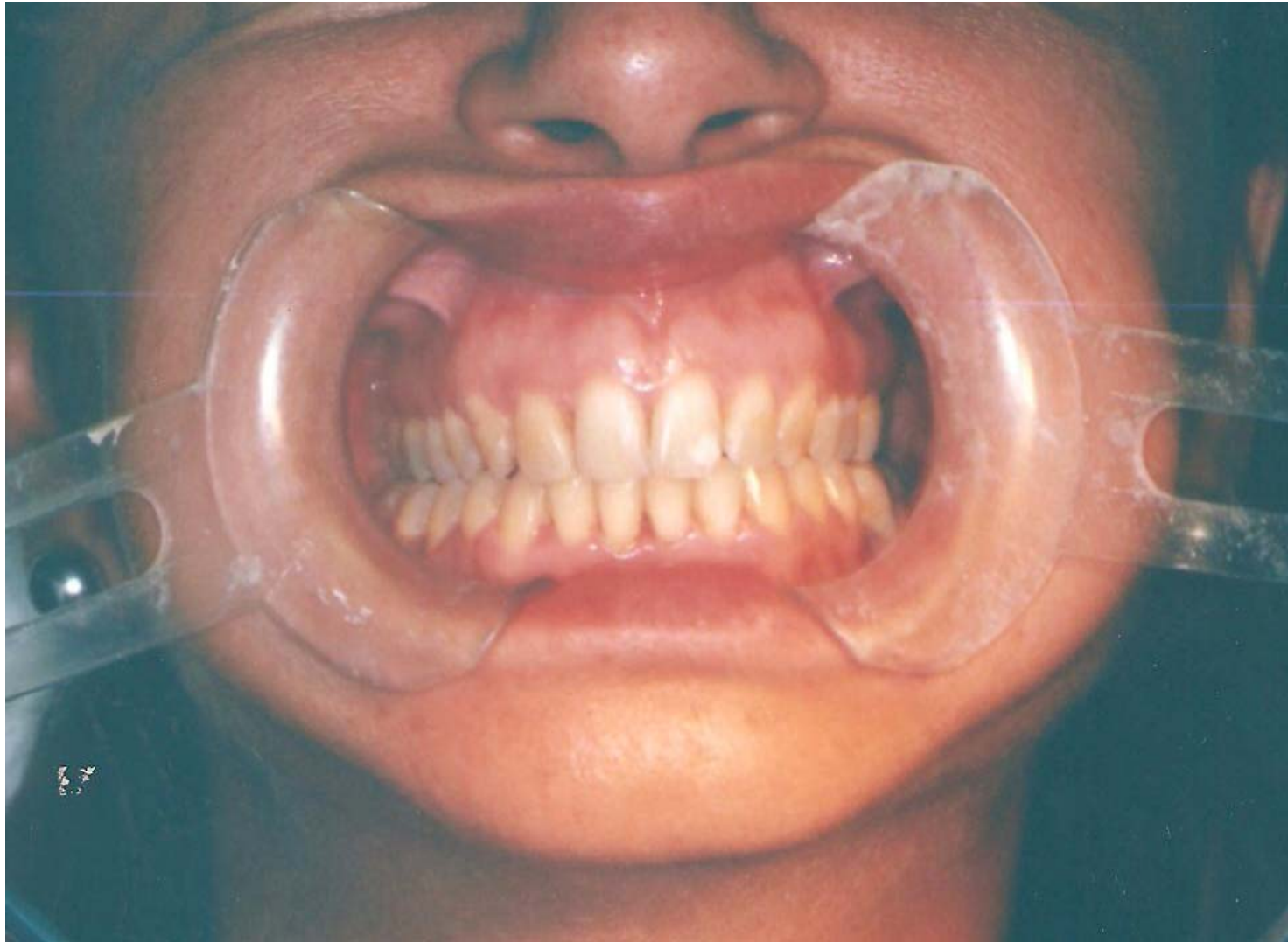
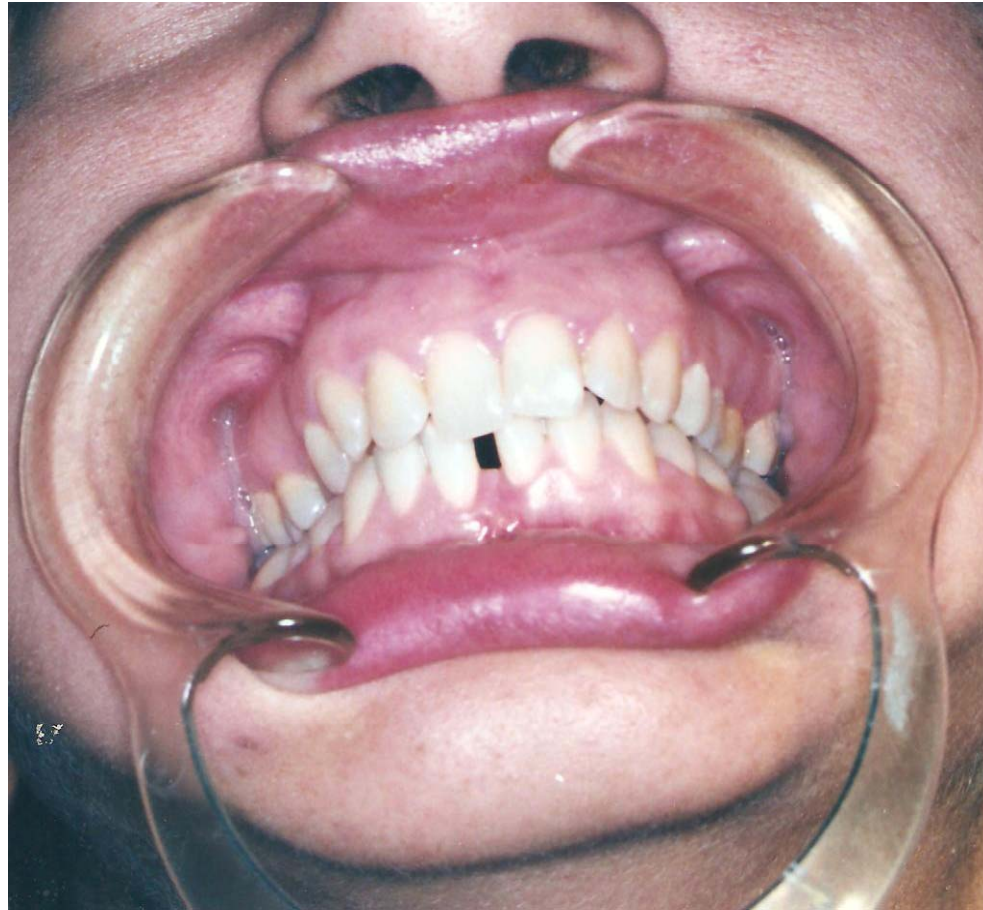


Case report n°6

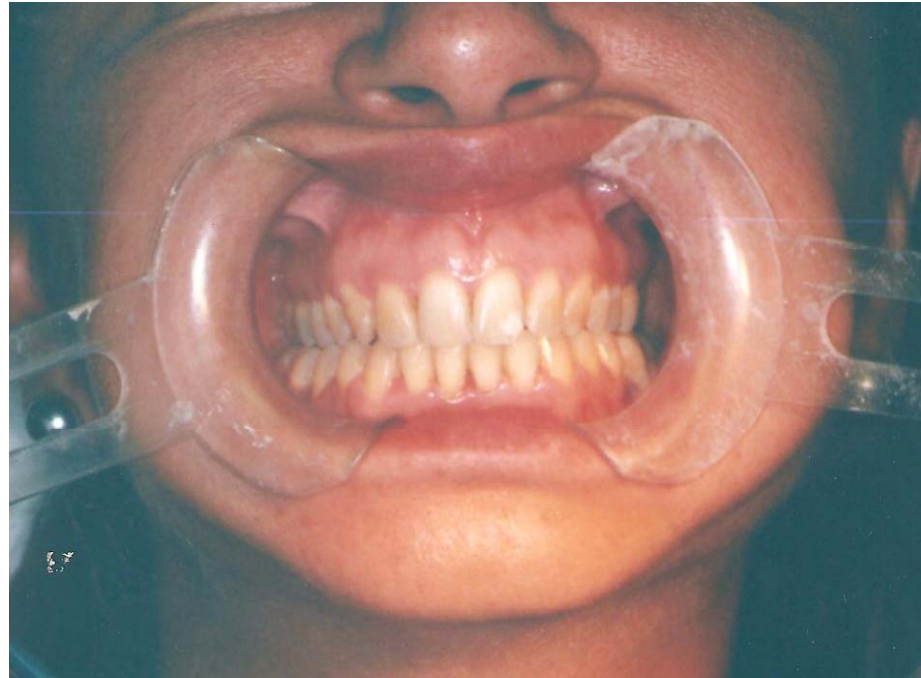
Paziente con intensa cefalea
cervicalgia perdurante da diversi anni,
completamente asintomatica dopo il
trattamento.



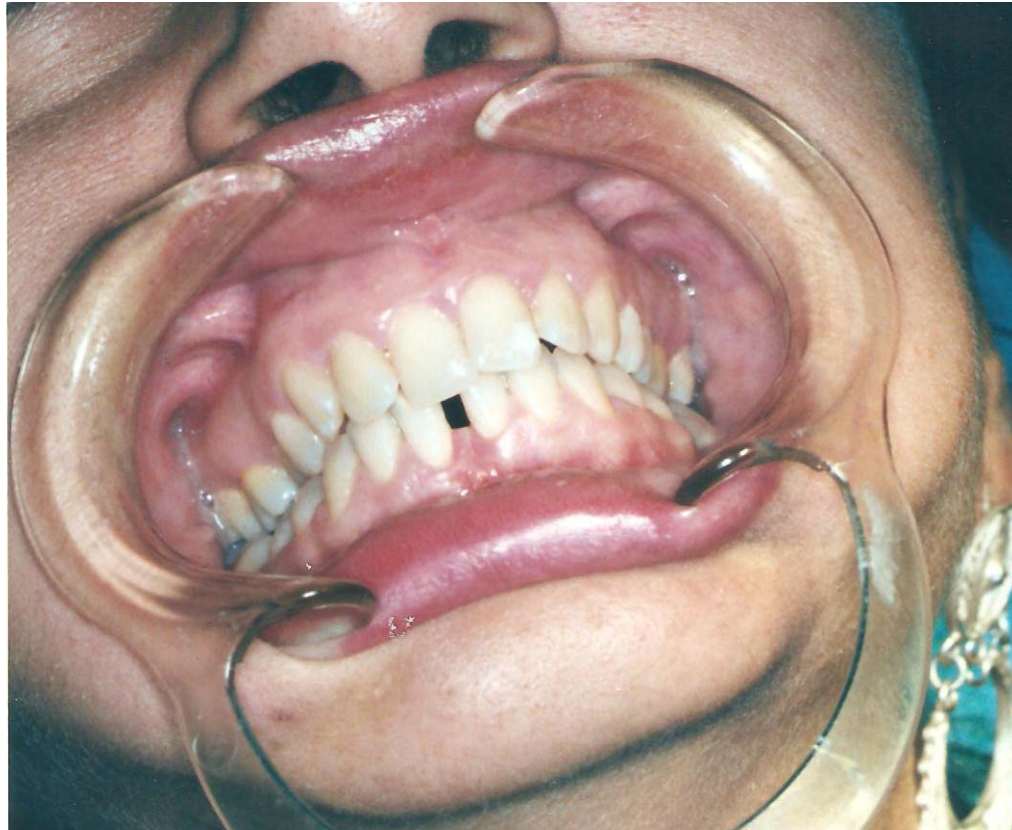
Prima del trattamento



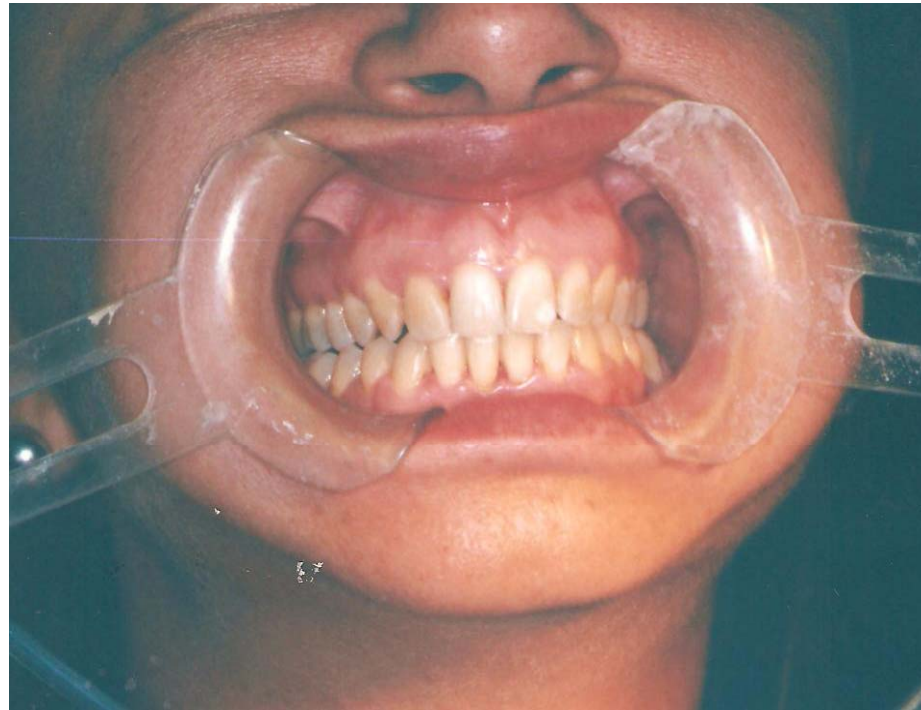
Dopo il trattamento



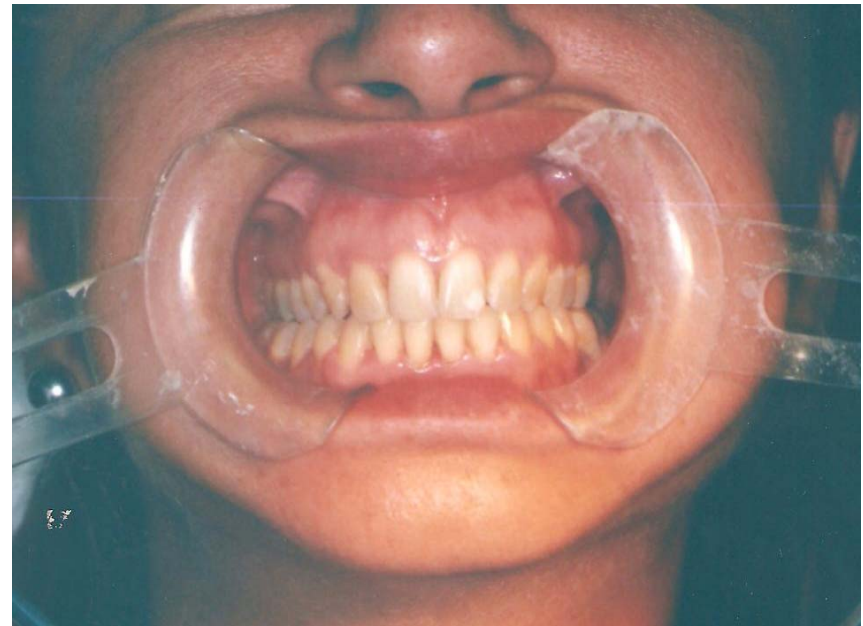
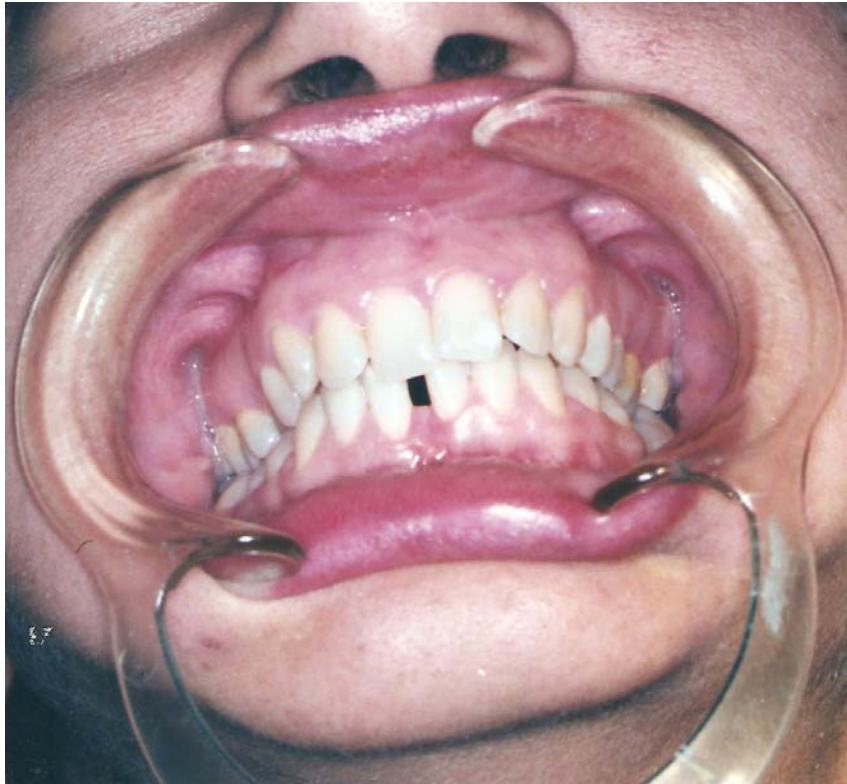
Prima del trattamento



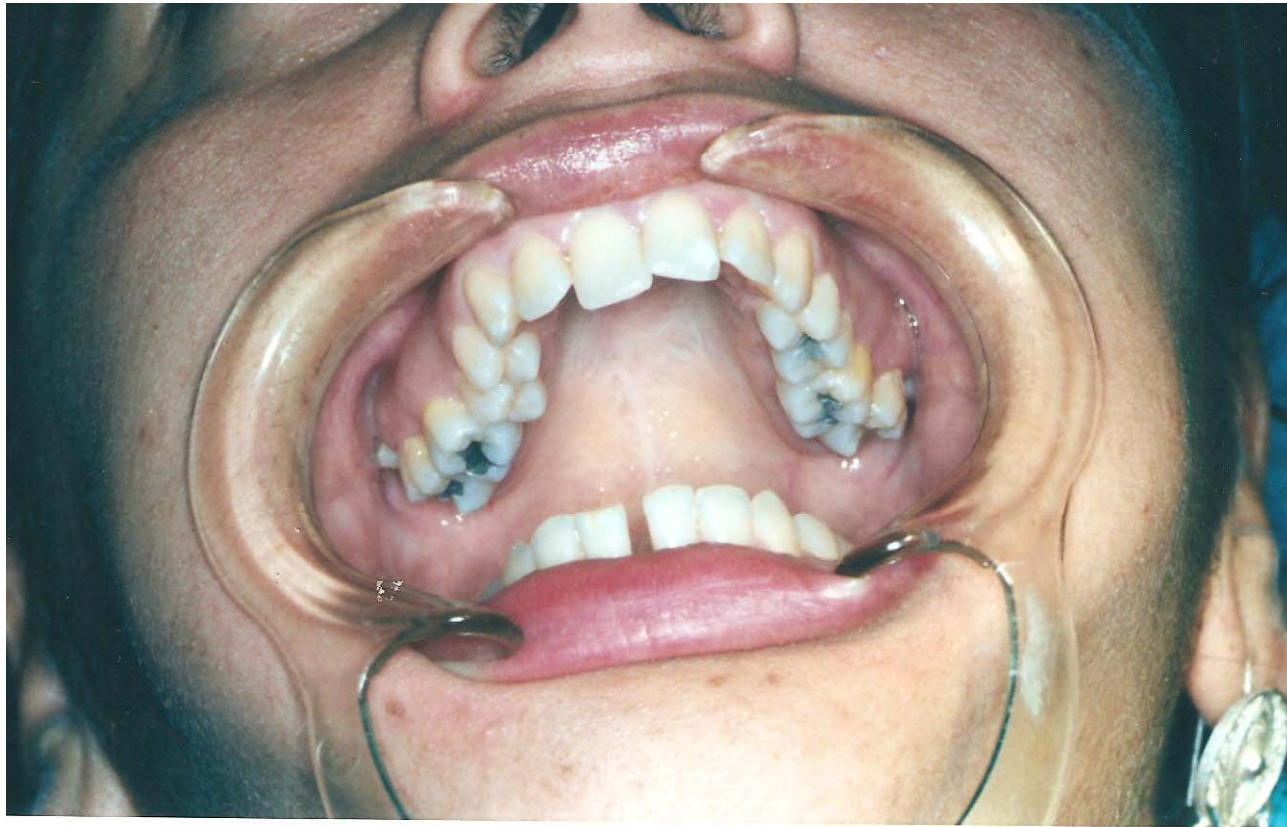
Dopo il trattamento



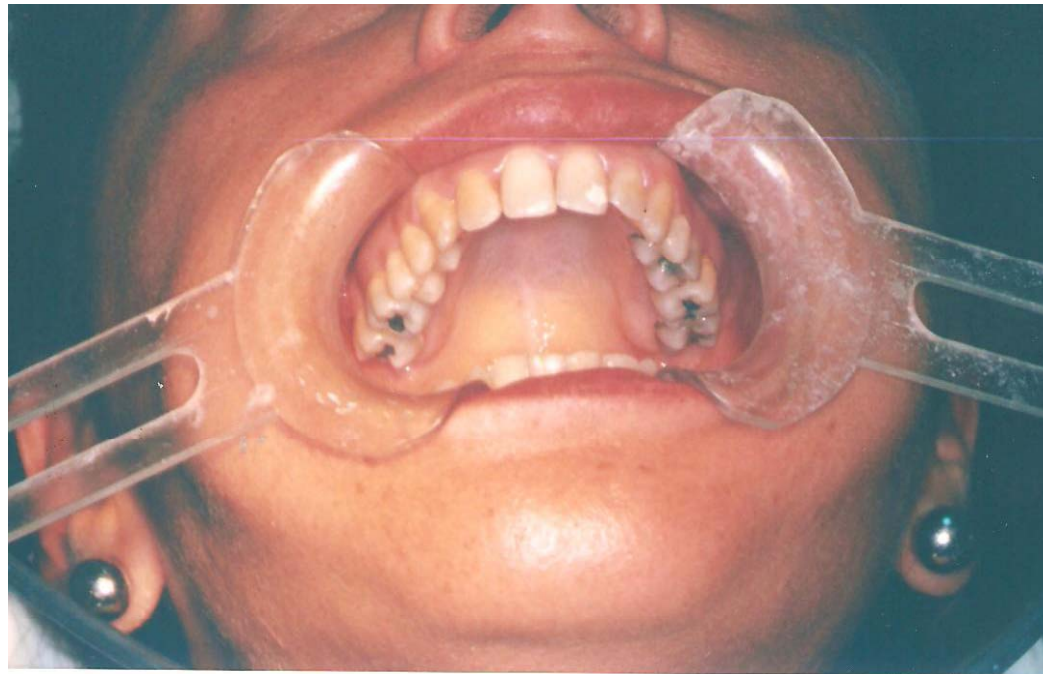
Confronto



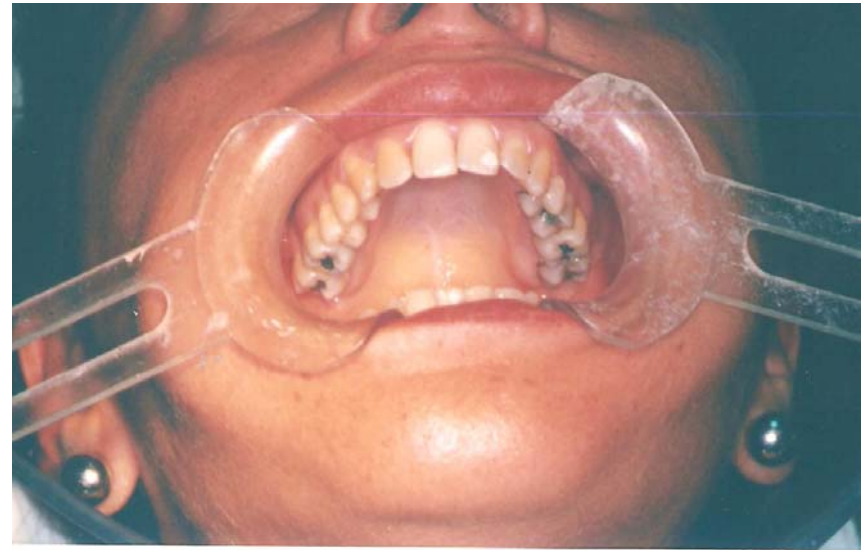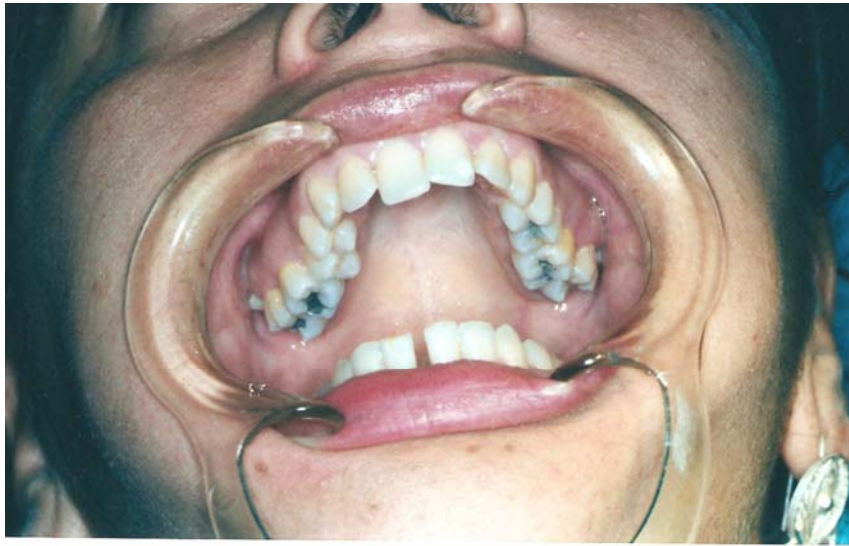
Prima del trattamento



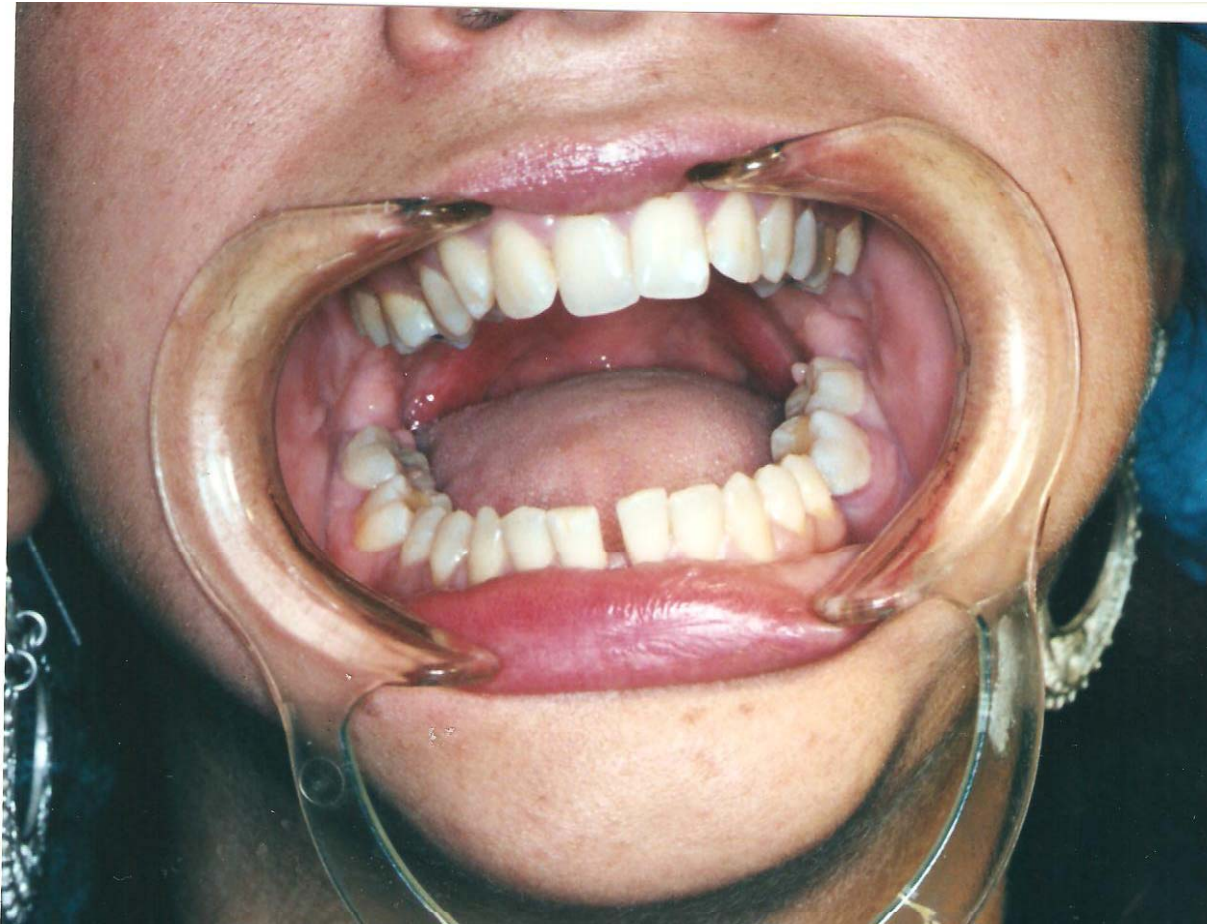Dopo il trattamento



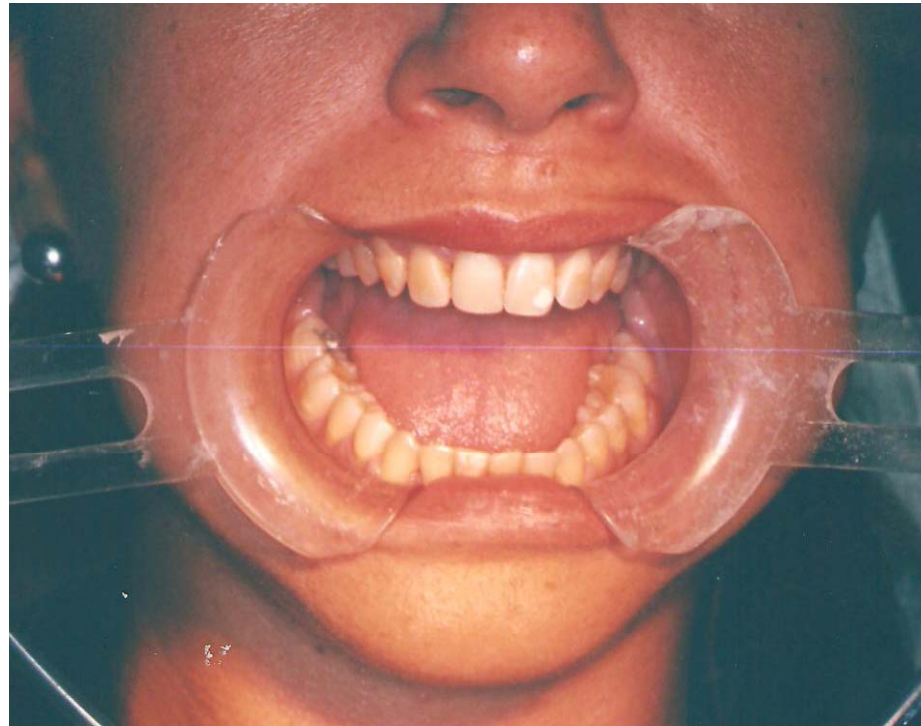
Confronto



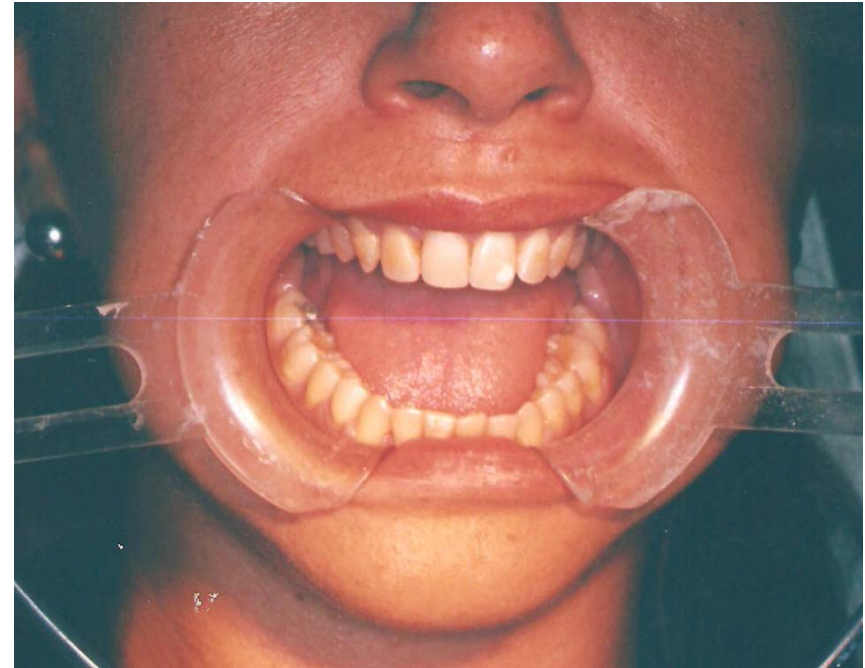
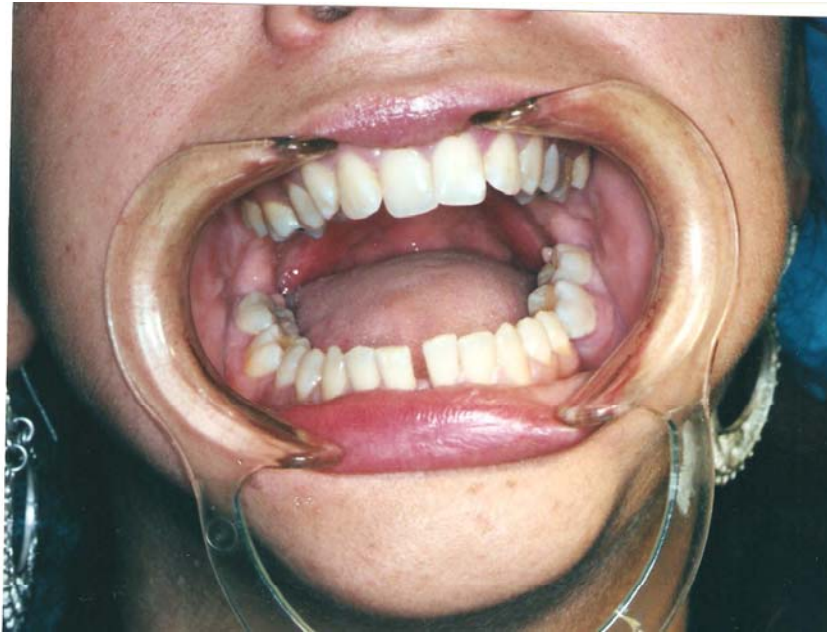Prima del trattamento



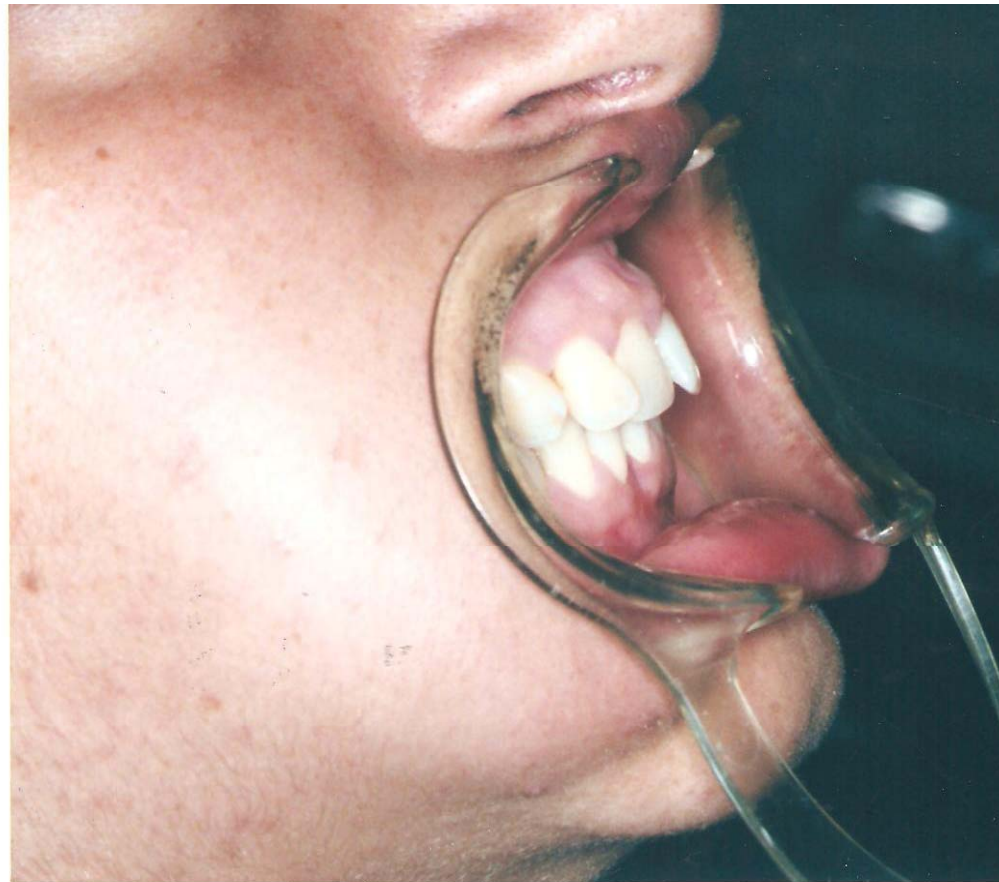Dopo il trattamento



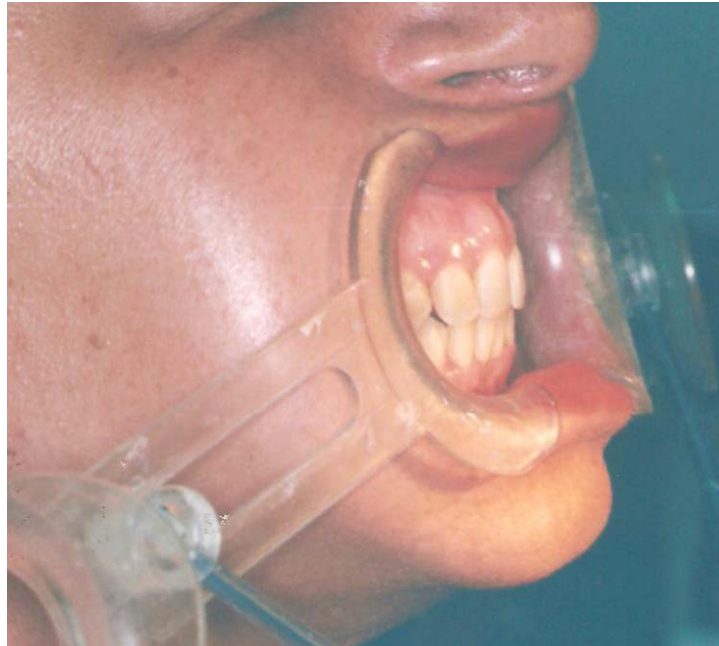
Confronto



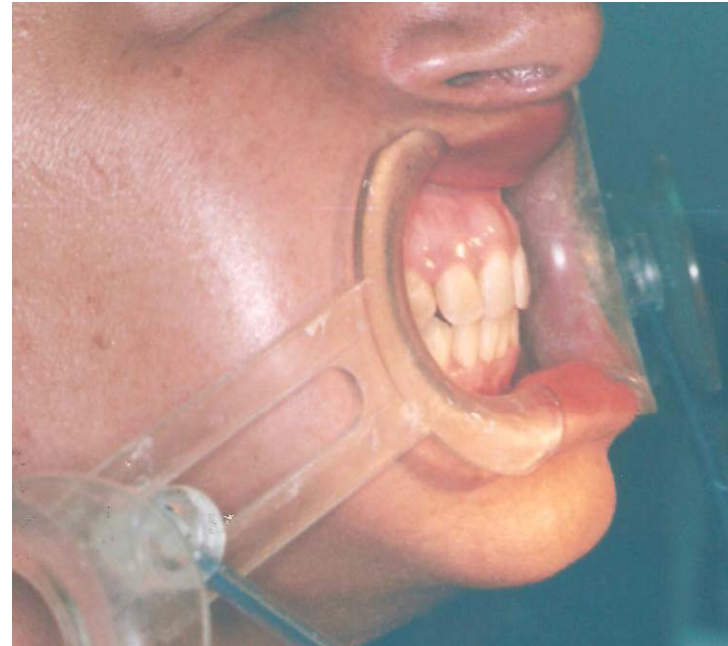
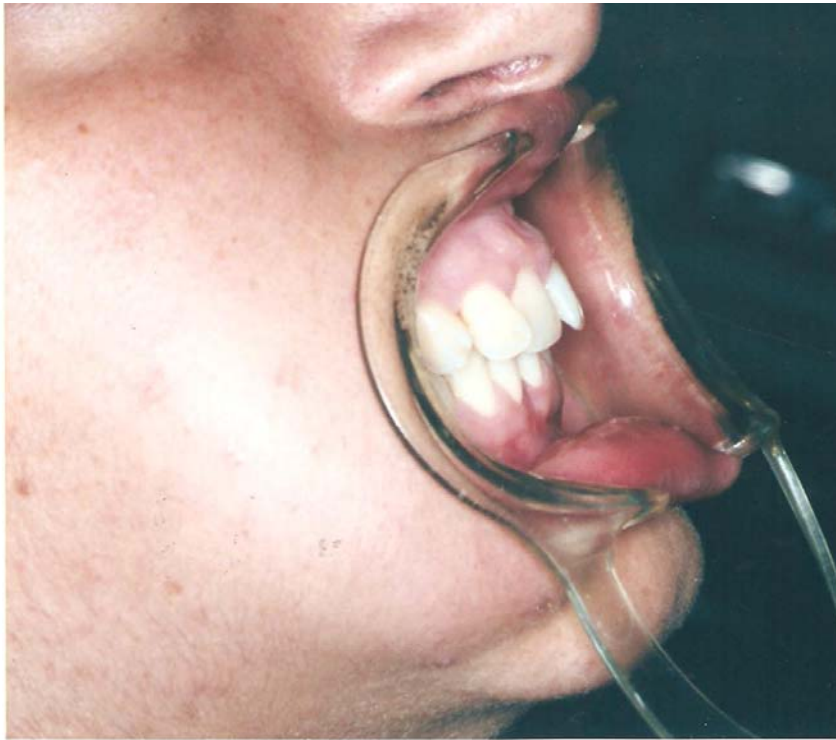
Prima del trattamento



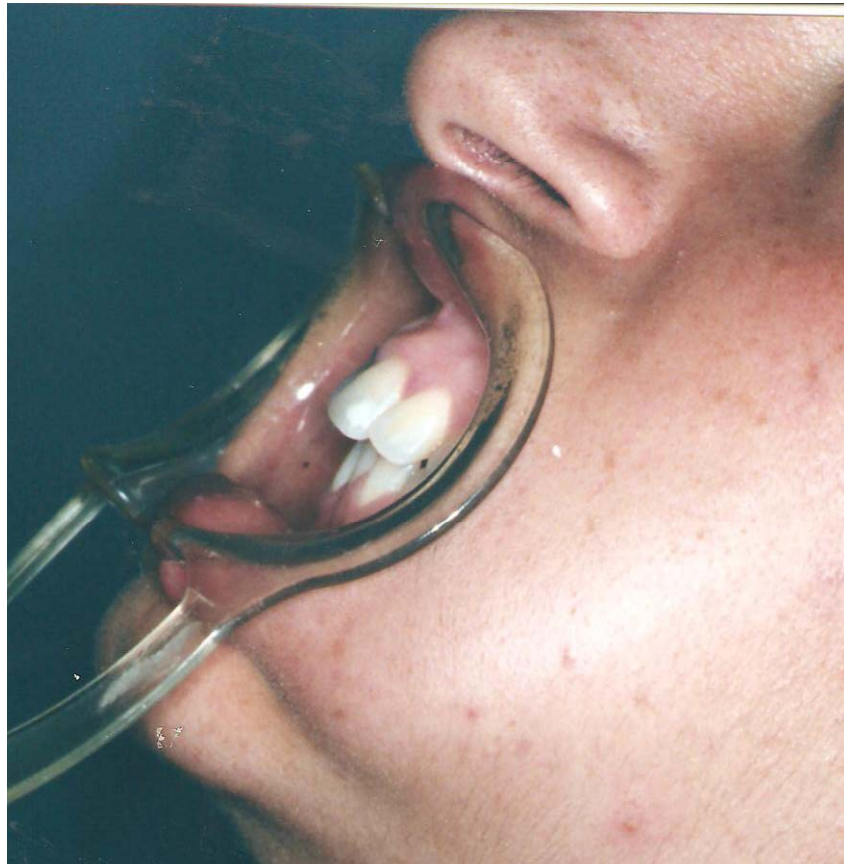
Dopo il trattamento



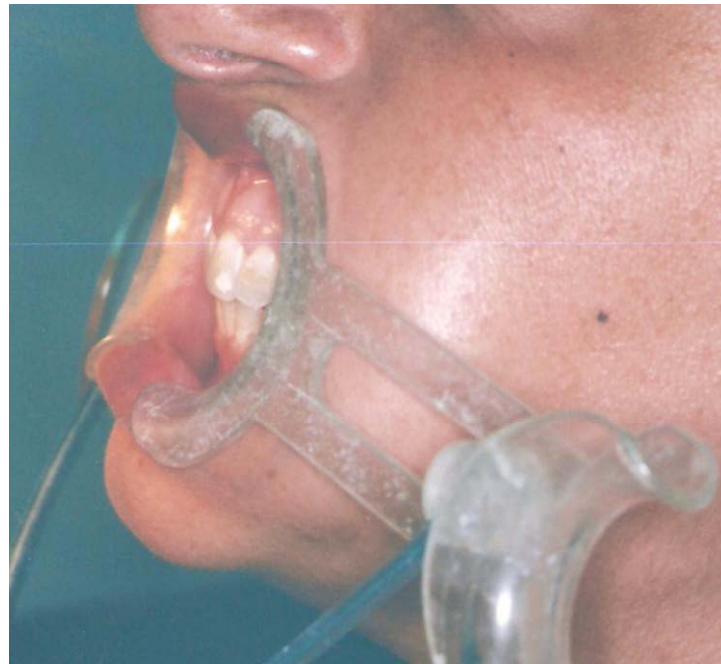Confronto



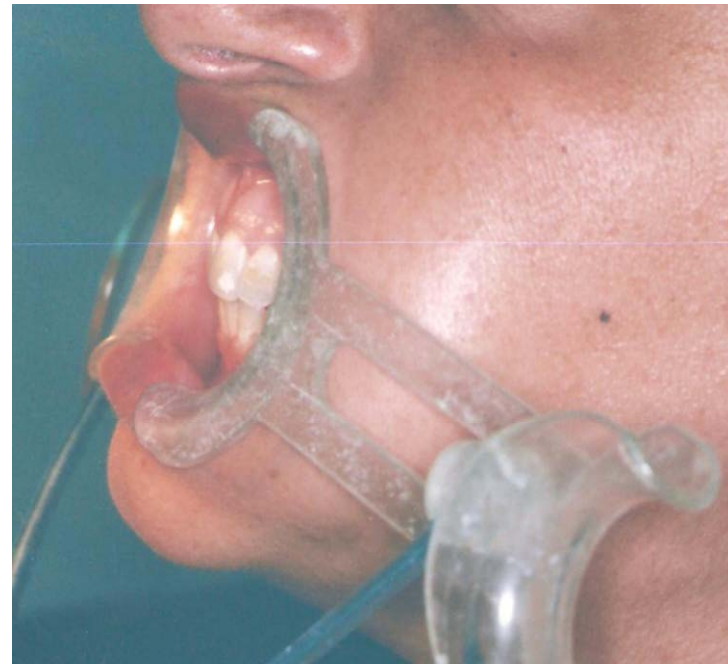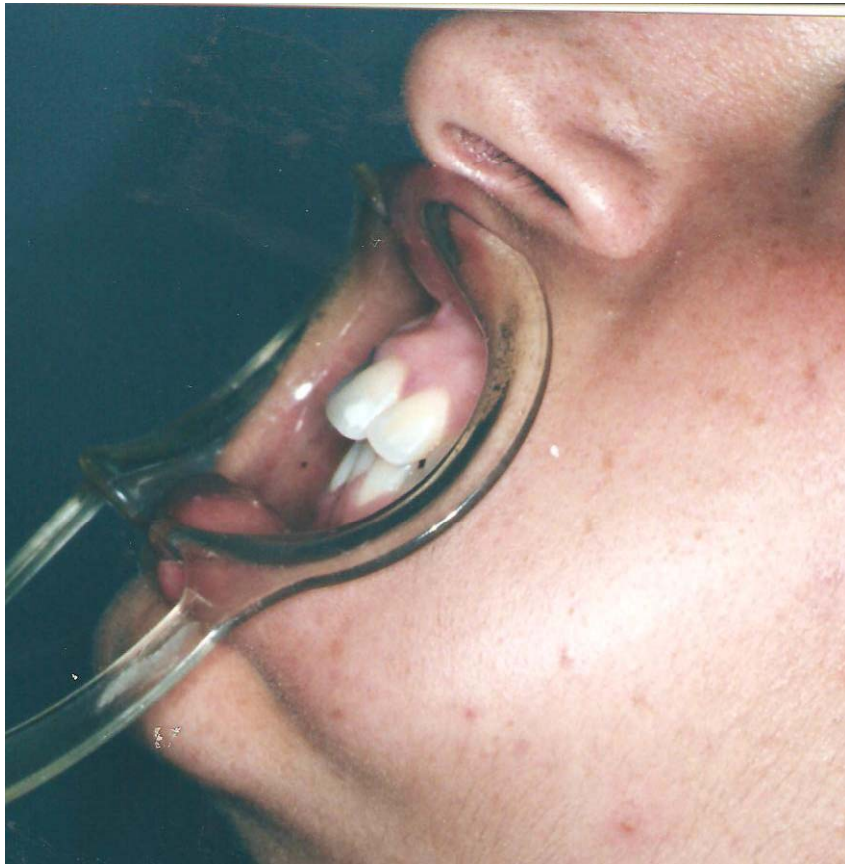
Prima del trattamento



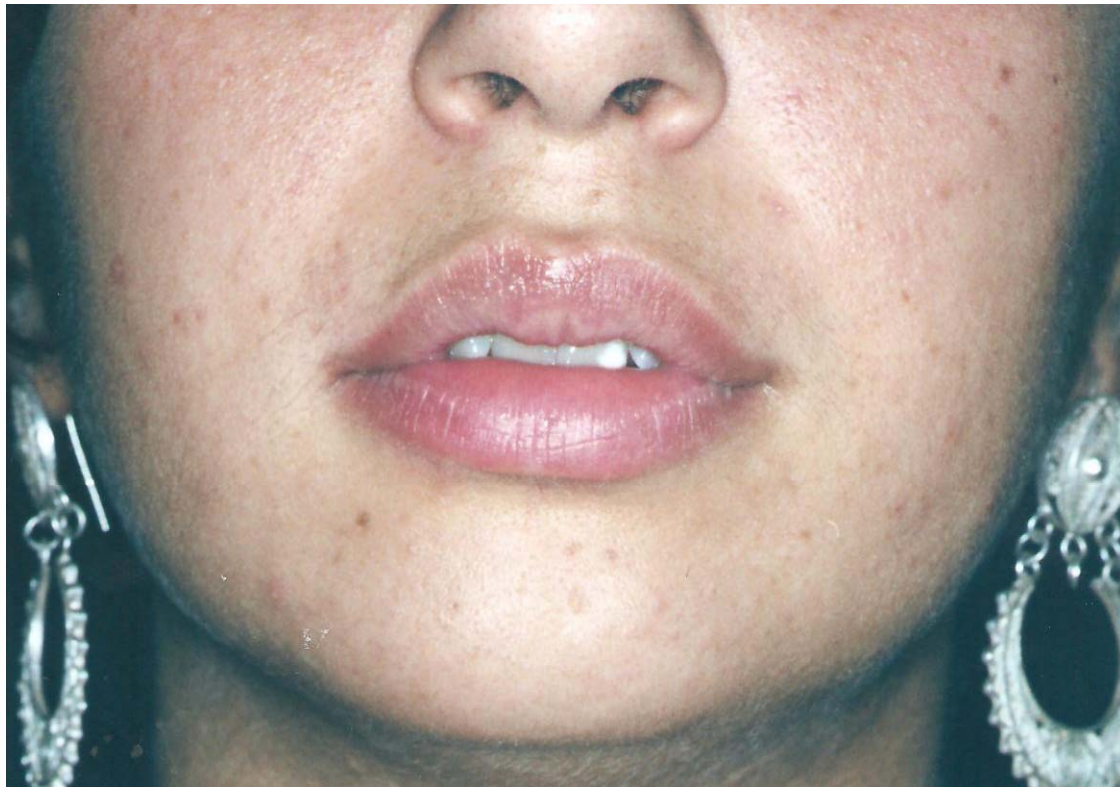Dopo il trattamento



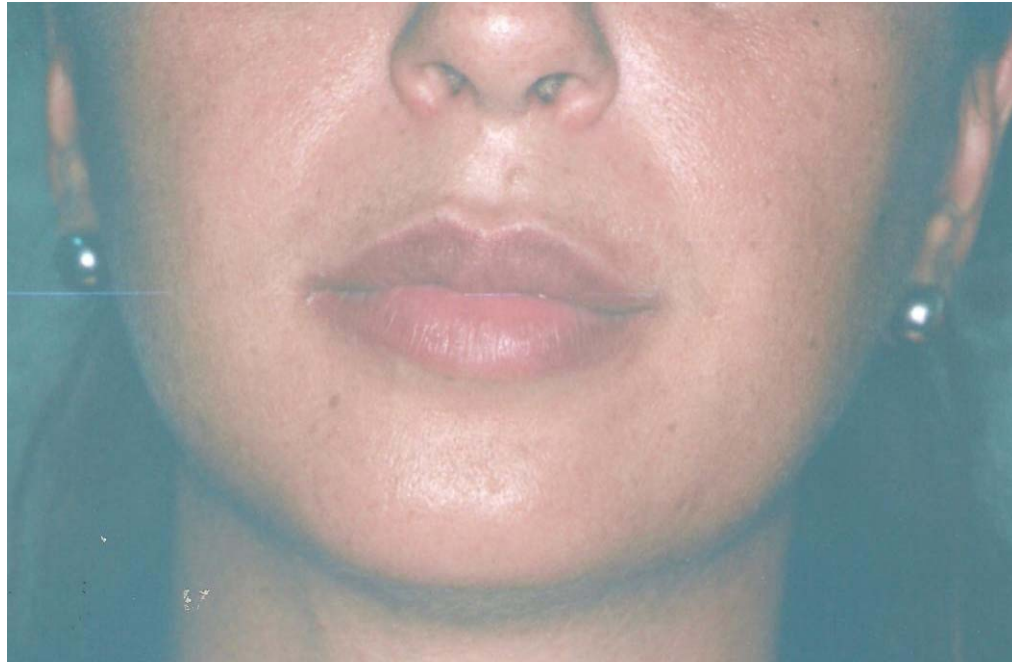Confronto



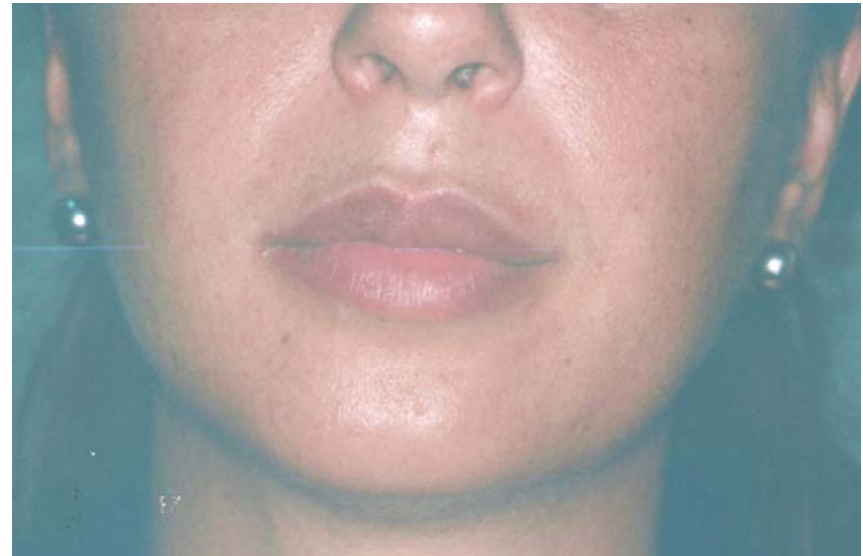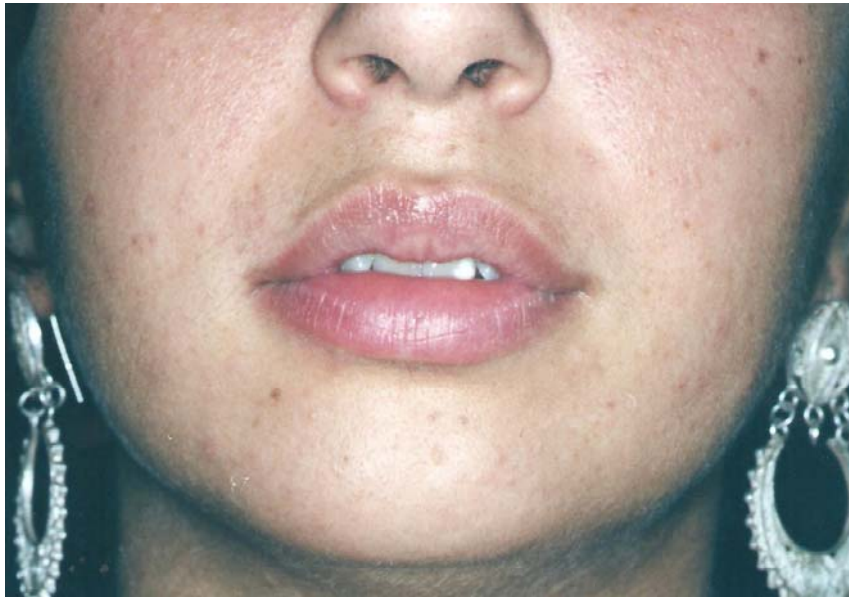Prima del trattamento



Dopo il trattamento



Confronto



Caso finito

